



Available online at  
**ScienceDirect**  
[www.sciencedirect.com](http://www.sciencedirect.com)

Elsevier Masson France  
**EM|consulte**  
[www.em-consulte.com](http://www.em-consulte.com)



## Review Article

# A systematic review of the neuroanatomy of dissociative identity disorder

David Blihar\*, Elliott Delgado, Marina Buryak, Michael Gonzalez, Randall Waechter

School of Medicine, St. George's University, True Blue, Grenada

### ARTICLE INFO

#### Article history:

Received 21 September 2019  
 Received in revised form 13 January 2020  
 Accepted 22 January 2020

#### Keywords:

Dissociative Identity Disorder  
 Multiple Personality Disorder  
 MRI  
 Neuroanatomy

### ABSTRACT

Dissociative Identity Disorder (DID) is a complex and controversial diagnosis that has undergone multiple revisions in the Diagnostic and Statistical Manual of Mental Disorders (DSM) since its recognition in the 1950s (North, 2015). There is not a clear understanding of DID etiopathology, there is no standardized method of diagnosis, and as such, the disorder has been plagued by a history of fabrication case studies (North, 2015). For these reasons, the disorder is opposed by many psychiatrists. To address this controversy, researchers have begun to examine the neurological basis of DID in an effort to provide stronger physical evidence for the disorder. While this line of inquiry is in its infancy, the purpose of the present systematic review is to examine the existing research on the neuroanatomical brain changes associated with DID in an effort to validate the disorder and provide a foundation for the future development of more accurate and reliable diagnostic techniques. When compared to the brains of normal controls, DID patients show smaller cortical and subcortical volumes in the hippocampus, amygdala, parietal structures involved in perception and personal awareness, and frontal structures involved in movement execution and fear learning. DID patients also show larger white matter tracts that are responsible for information communication between somatosensory association areas, basal ganglia, and the precuneus. These neuroanatomical changes appear to be associated with common DID symptoms such as host dissociation, neurotic defense mechanisms, and overall brain activation/circuitry recruitment. This is the first study to systematically review existing MRI data on DID patients and link it to common behavioral symptoms seen with the disorder. The neuroanatomical evidence for the existence of DID as a genuine disorder is growing and the structural differences seen in DID patients' brains, as reviewed in this report, contribute to that growth.

© 2020 The Authors. Published by Elsevier Masson SAS. This is an open access article under the CC BY-NC-ND license (<http://creativecommons.org/licenses/by-nc-nd/4.0/>).

## 1. Introduction

Although DID has been recognized in the Diagnostic and Statistical Manual of Mental Disorders (DSM) since the 1980s, the disorder has remained controversial (APA, 2013). The validity of the diagnosis is often called into question because of the lack of reliable diagnostic measures (Reinders, Willemsen, Vos, & Boer,

2012; van Ijzendoorn & Schuengel, 1996; Weniger, Lange, Sachsse, & Irle, 2008). The existence of DID continues to be debated because of a lack of understanding of the etiopathogenesis of the disorder (Brand et al., 2016; Merckelbach, Lynn, & Lilienfeld, 2016; Vissia et al., 2016). Patients with DID often suffer years of misdiagnosis with incorrect treatment; this is most likely a result of psychiatrists being unfamiliar with the disorder and DID patients attempting to mask symptoms out of shame (Reinders et al., 2019; Spanos, 1994).

### 1.1. Diagnostic Measures

The methods used for qualifying and quantifying DID are not able to be standardized and have been deemed unreliable (Elzinga, Dyck, & Spinhoven, 1998). Current methods for aiding the diagnosis of DID are the Structured Clinical Interview for DSM-IV Dissociative Disorders (SCID-D), Multidimensional Inventory of Dissociation (MID), and the Dissociative Experiences Scale (DES);

*Abbreviations:* BG, bilateral gray matter; BW, bilateral white matter; CT, Cortical Thickness; CV, Cortical Volume; LE, entire gray and white matter of left hemisphere structure; LG, left hemisphere gray matter; LW, left hemisphere white matter; RE, entire gray and white matter of right; RG, right hemisphere gray matter; RW, right hemisphere white matter; SA, surface area; TE, total gray and white matter of entire structure; TG, total gray matter; TW, total white matter; USDHSS, US Department of Health and Human Services.

\* Corresponding author.

E-mail addresses: [dblihar@sgu.edu](mailto:dblihar@sgu.edu) (D. Blihar), [edelgad2@sgu.edu](mailto:edelgad2@sgu.edu) (E. Delgado), [mburyak@sgu.edu](mailto:mburyak@sgu.edu) (M. Buryak), [mgonzal4@sgu.edu](mailto:mgonzal4@sgu.edu) (M. Gonzalez), [rwaechte@sgu.edu](mailto:rwaechte@sgu.edu) (R. Waechter).

<https://doi.org/10.1016/j.ejtd.2020.100148>

2468-7499/© 2020 The Authors. Published by Elsevier Masson SAS. This is an open access article under the CC BY-NC-ND license (<http://creativecommons.org/licenses/by-nc-nd/4.0/>).

which are symptom measurement scales. The DES was developed from interview data that met DSM-III criteria for dissociative disorders in order to increase the reliability and efficacy of a dissociative diagnosis (APA, 2013). However, many skeptics criticize these measures on the grounds of subjective reporting and interpretation. For example, the DES has been shown to have predictive validity but no discriminant validity has been established (van Ijzendoorn & Schuengel, 1996). Research has been conducted on the strength and reliability of the DES, but the validity studies have been accused of *circulus in probando* (Elzinga et al., 1998). Some other criticisms of the DES and the MID, are that it requires a high-school reading level and is sensitive to response and experimenter biases (van Ijzendoorn & Schuengel, 1996; Weniger et al., 2008). In comparison to the DES and MID, the SCID-D has received far less criticism (Ross, 1998; Steinberg & Hall, 1997; van Ijzendoorn & Schuengel, 1996). There is not a gold standard of high sensitivity and specificity with minimal subjective interpretation so there is no way to verify any of the dissociative symptoms measures, which results in the use of a non-standardized measure to validate a non-standardized measure (APA, 2013; Elzinga et al., 1998; van Ijzendoorn & Schuengel, 1996).

### 1.2. Etiopathology

Along with a lack of validity, there is a lack of understanding regarding the etiopathology of DID. Many researchers and psychiatrists regard DID as the most severe form of a childhood onset Post-Traumatic Stress Disorder (PTSD) because it is virtually impossible to find a DID patient without a history of PTSD (Chalavi, 2013; Ehling, Nijenhuis, & Krikke, 2007; Vermetten, Schmahl, Lindner, Loewenstein, & Bremner, 2006; Weniger et al., 2008). Further, DID shares many features of PTSD with the addition of identity disruption in two or more distinct personalities (Chalavi et al., 2015b). There are currently two competing theories regarding the relationship between trauma and dissociation: the trauma-related model and the fantasy-prone model.

#### 1.2.1. The Trauma-Related Model

The trauma-related model states that severe early childhood abuse increases the risk for the development of dissociation. Stein, Koverola, Hanna, Torchia, and McClarty (1997) showed that patients who had suffered childhood abuse had a significant reduction in hippocampal volume with a higher DES score (1997); Irle, Lange, Weniger, and Sachsse (2007) also observed an increase in dissociative symptoms in survivors of childhood abuse. Despite the existing data supporting this theory, many psychiatrists and psychiatric researchers remain unconvinced (Irle et al., 2007; Reinders et al., 2012). Another issue with validating this model is the difficulty in assessing trauma via retrospective recall. The ability to accurately remember forgotten or dissociated memories under hypnosis has been disputed since before the creation of the DID diagnosis. Patients may fabricate the actual trauma or exaggerate what they experienced (Elzinga et al., 1998; Şar, Dorahy, & Krüger, 2017). Studies have attempted to control for the possibility of faking dissociative symptoms and concluded differences exist between DID patients and fabricated trauma (Reinders et al., 2012). However, the amnesia that dissociative patients experience cannot be replicated clinically which limits the applicability of false memory research.

#### 1.2.2. The Non-Trauma Related Model (Sociocognitive Model)

The *non-trauma related model*, or *Sociocognitive model* or *Fantasy model*, states that dissociative symptoms in DID are caused by simulation, suggestive psychotherapy, and/or sociocultural influences (Reinders et al., 2012). This theory suggests that the

development of DID is mediated by high fantasy proneness (Chalavi, Vissia, Giesen, Nijenhuis, Draijer, Barker et al., 2015a; Dalenberg et al., 2012). Based on DSM-5 criteria, the form in which DID takes shape is influenced by the patient's culture (APA, 2013). Moreover, alters take the form of figures within the patient's social constructs, for example: demons or an identity in India speaking fluent English and exclusively wearing Western clothes (APA, 2013; Reinders et al., 2012). The Sociocognitive model suggests that DID patients are highly hypnotizable and very influenceable indicating the possibility that they would be prone to suggestions (Chalavi, Vissia, Giesen, Nijenhuis, Draijer, Cole et al., 2015; Reinders et al., 2019; Schlumpf et al., 2013).

### 1.3. "Hollywoodization"

The final point of controversy is whether DID patients are simply malingering (Dalenberg et al., 2012; McAllister, 2000). Moreover, there is concern that symptoms of DID are fabricated by people who have personality disorders or that the symptoms are falsely attributed by eager therapists (McAllister, 2000). For example, a therapist may recognize a small number of DID symptoms and tailor his/her examination to diagnose DID (iatrogenic DID). An example of this "Hollywoodization" was the controversy plaguing the book *Sybil* (Schreiber, 1973). Reinders et al. (2019) stated that *Sybil* was "a manufactured iatrogenic case of multiple personalities". Some psychiatrists believe that the stigma of DID for fame and recognition created by the media was a fueling factor for the diagnosis change from MPD to DID (Reinders et al., 2019; Schlumpf et al., 2013). Rather, the American Psychological Association (APA) pushed for the change because many movies and television shows portrayed DID in a negative, irrational, or violent light (APA, 2013; Reinders et al., 2012). Further, therapist misattribution of symptoms for fame has been proposed as a likely reason for the increase in DID diagnoses from 1 case per year in the 1970s to 60 cases per year in the 1990s (McAllister, 2000); similarly, the notion that symptoms are easily recreated has also been seen in criminal cases that have acted out DID in support of a criminal insanity plea (Chalavi, 2013; Reinders et al., 2019, 2012). Such was the case of Kenneth Bianchi (Watkin, 1984). This Hollywoodization of the disease, copycat behavior and therapist attribution of symptoms could be responsible for the increases in DID cases.

### 1.4. Systematic Review Purpose & Rationale

The purpose of this systematic review is to compile and examine the peer-reviewed literature on the neuroanatomy associated with DID diagnosis measured using magnetic resonance imaging (MRI). The rationale for this review is that compiling the data will lend validity to the existence of the disorder, provide a foundation for more reliable diagnostic criteria, and reveal any potential research gaps. Implications of the neuroanatomical basis of DID have been highlighted by current leaders in this field of research. Reinders et al. (2019) have shown that DID patients and healthy controls (HC) can potentially be discriminated using patterns of neuroimaging biomarkers. Chalavi et al. (2015b) have documented the extensive differences in the neuroanatomy of DID patient brains compared to PTSD patients and healthy controls. Schlumpf et al. (2013) have previously reported the differences in neural structure activation and utilization during facial recognition in DID patient brains compared to healthy controls. These results suggest that the morphological differences might aid in the accurate and reliable diagnosis of DID. This systematic review hopes to offer evidence for the validity of DID as a diagnosis by compiling these biomarkers. While biomarkers do not have to be present for the existence of a disorder, the presence of

neuroanatomical biomarkers will lend significant strength to the validity of the disorder. This review also aims to document measurable changes in DID patients that can drive future research to develop more accurate and reliable diagnostic techniques.

## 2. Methods

### 2.1. Protocol Registration

This protocol is registered with PROSPERO (NIH, n.d.) under Registration Number: CRD42019125573. This manuscript conforms to PRISMA reporting guidelines for systematic reviews and meta-analyses (Shamseer et al., 2015).

### 2.2. Rationale for restriction to MRI

A cursory literature search prior to drafting this protocol revealed a large amount of research into neurological measures of DID including: electroencephalogram (EEG), computerized axial tomography (CT), positron emission tomography (PET), and single-photon emission computed tomography (SPECT). The aim of this study was to discuss the neuroanatomy of the brain, through volumetric and thickness data of brain structures, gray matter, and white matter. EEG measures electrical activity of the brain and provides no information on structural changes of brain tissue. CT scan resolution is not high enough to quantify cortical thickness (CT) and structure volume (Chang, Rowland, & Barbaro, 2012; Schmidek & Sweet, 2012; Weingarten et al., 2009). PET scan provides metabolic information about brain tissue. SPECT resolution is lower than PET and measures regional cerebral blood flow (rCBF). Functional Magnetic Resonance Imaging (fMRI) measures perfusion rates in the brain using a fast fourier transform (FFT) of MRI data but MRI is measured as part of the FFT. Studies that reported fMRI data were excluded as they did not report structural volume. Therefore, the protocol was limited to only MRI in order to obtain studies with the data that would address the study aim.

### 2.3. Search Criteria

The present work adopts a similar search procedure to Pham et al. (2014). The initial data search was conducted across six electronic databases: PubMed, Psychiatry Online, MedLinePlus, ScienceDirect, Cochrane, and PsycINFO using the Boolean search: (“Dissociative Identity Disorder” OR “Multiple Personality Disorder”) AND MRI.

No filters were placed on search results. Predefined keywords, such as “Dissociative Personality Disorder”, “Multiple Personality Disorder”, and/or “MRI,” had to be included in article abstracts unless the methodology section included brain measurements of DID participants. Articles that included PTSD subjects in addition to DID participants were considered. A similar search of Google Scholar was also conducted. The first 100 hits were screened, as sorted by relevance by Google. Current leaders in DID neuroanatomy research, Dr. Yolanda Schlumpf, Dr. Sima Chalavi, and Dr. Antje A T S Reinders, were contacted in order to gather any unpublished data. None of the authors reported any new data or awareness of other researchers with unpublished data.

### 2.4. Inclusion and exclusion criteria

#### 2.4.1. First inclusion eligibility criteria (title and abstract)

All hits from the initial Boolean search were screened both by title and abstract for relevance to the research question. Articles that progressed to second inclusion criteria discussed imaging the brains of DID patients using MRI drew conclusions pertaining to a

structural component of the brain. Articles also passed the first inclusion criteria if they discussed: measuring metabolic changes in brain tissue of DID patients using fMRI, potential biological, or biopsychosocial causes of DID.

#### 2.4.2. Second inclusion eligibility criteria (results and discussion)

All articles that passed the first inclusion criteria were reviewed for pertinence to the research question. Four reviewers were randomly assigned into two groups. Articles were then randomly assigned to each group so that all articles were reviewed by two reviewers in order to reduce bias. The articles were thoroughly reviewed for:

- a numerical quantification of changes in the neuroanatomy of DID patients and;
- a discussion of possible implications of the data.

In the event that disagreement on inclusion arose, a third reviewer made the conclusive decision.

#### 2.4.3. Snowball search

Citations within eligible articles passing 2.4.2 were searched for relevance to the review (Pham et al., 2014). Any hits were then subjected to the above criteria.

#### 2.4.4. Final inclusion eligibility criteria (quality of the study)

The final inclusion criterion was the quality of each study measured using the scoring system outlined by the US Department of Health and Human Services (USDHSS) (West et al., 2002). Articles that had a quality rating of greater than or equal to 4 were accepted for data extraction. Table 1 shows how the strength of the study was calculated. Table 2 shows what each included study strength was. A PRISMA flow chart was generated upon completion of the selection and exclusion process Fig. 1.

#### 2.4.5. Data extraction and reporting

Included studies were combed for structural changes in brain tissue. Statistical  $p$  values and percent differences in brain tissue were taken from each published paper. If percent difference was not listed, the percent was calculated from the data in the paper using  $100 \times [(\text{Observed} - \text{Expected}) / \text{Expected}]$  where Observed was the DID patient result and Expected result was the healthy control. During initial review of Reinders et al., 2019, it was noticed that they reported data as embedded in a pattern of voxels and not as local univariate statistics. Therefore, any efforts to quantify percent differences in individual regions was abandoned. Instead, the decision was made to report the  $p$  values and the (+) or (−) mapping sign. To clarify this confusion, a statement has been added to the legend of Supplemental Table 1.

## 3. Results

The following subsections summarize differences seen in neuroanatomy among DID patients compared to patients without DID and/or healthy controls (HC). All volume percent differences and corresponding  $p$ -values are given in Supplemental Table 1.

### 3.1. Whole Brain

Irle et al. (2007) did not find significant differences in brain total entire structure (TE) between DID patients and BPD patients. Weinger et al. (2008) did not find significant differences in TE between PTSD/DID patients and HC. Chalavi et al. (2015a) found that the cortical volume (CV) of total gray matter (TG) ( $p = 0.003$ ), left hemisphere gray matter (LG) ( $p = 0.001$ ), and right hemisphere

**Table 1**  
The USDHSS guidelines on how to determine the strength of an article.

Study Quality Score	0	1	2
Data analysis	Justification of outcomes measures not described or validated, unnecessary potential for bias, or statistical methods not appropriate for study data	Limitations in collection and analysis of data are generally recognized and explained by study	Outcome is hypothesis-driven, reliable, measures are reliable and validated to reduce measurement bias, and appropriate explanation for statistical analysis
Intervention	Lacking detailed description about the intervention components and protocol	Comprehensive cognition assessment program of long-term fluoxetine patients with mention of several components (i.e. memory, cognition, and cortical function)	Well-described program, including cognition assessment program including type of memory, processing speed, cognitive adaption, etc.
Sample size (final data set)	0–10 per group	11–20 per group	> 20 per group
Study design	Uncontrolled	Matched or convenience controlled (i.e. comparing pre-existing groups)	Randomized, controlled trial

gray matter (RG) ( $p = 0.009$ ) were significantly smaller than healthy controls. Chalavi et al. (2015b) and Vermetten et al. (2006) found no significant difference in the CV of total brain parenchyma between DID patients and HC. Tsai, Condie, Wu, and Chang (1999) found that the cortical volume of their DID patient was within normal limits (WNL). The CT of brain LG was observed to be smaller in DID patients (Chalavi et al., 2015b).

### 3.2. Frontal lobe

#### 3.2.1. Global frontal lobe

Chalavi et al. (2015a) found that the total frontal lobe gray matter ( $p = 0.002$ ), left frontal lobe gray matter, and right frontal lobe gray matter was significantly less ( $p = 0.006$ ) in DID-PTSD patients as compared to healthy controls. The global SA of the frontal lobe was significantly smaller but right frontal lobe surface area was significantly larger (Chalavi et al., 2015b). Also, the CT of the left lobe was observed to be significantly smaller in DID patients (Chalavi et al., 2015b).

#### 3.2.2. Surface frontal regions

Reinders et al. (2019) found that the volume of gray matter in the left and right superior frontal gyrus in DID patients was smaller compared to HC. They also found smaller CT and CV of the right superior frontal gyrus gray matter as well as smaller CT, SA, and CV of the left superior frontal gyrus gray matter (Reinders et al., 2018). The volume of the left superior frontal sulcus gray matter and bilateral superior frontal sulci gray matter were found to be larger and smaller, respectively (Reinders et al., 2018). Smaller gray matter CVs were found in the left superior medial frontal gyrus, left and right middle frontal gyrus, left and right medial frontal gyrus, left inferior frontal gyrus, and left frontal pole (Reinders et al., 2018, 2019). Reinders et al. found that the rostral middle frontal gyrus had smaller right hemisphere gray matter SA, left hemisphere gray matter CV, and right hemisphere gray matter CV (Reinders et al., 2018). Reinders et al. (2018, 2019) found that, in DID patients, the precentral gyrus had smaller left hemisphere gray matter CV and left hemisphere gray matter CT.

#### 3.2.3. Pars regions

Reinders et al. (2018) found that left hemisphere gray matter CT and CV and right hemisphere gray matter SA and CV were smaller in the pars triangularis and pars orbitalis of DID patients. The pars opercularis was found to have smaller left hemisphere gray matter CT and CV as well as smaller right hemisphere gray matter CV (Reinders et al., 2018).

#### 3.2.4. Ventral and deep frontal structures

The orbito-frontal cortex was found to have smaller right hemisphere gray matter CV in DID patients (Reinders et al., 2018). The lateral orbito-frontal cortex was found to have smaller left

hemisphere gray matter CT and CV as well as right hemisphere gray matter SA in DID patients (Reinders et al., 2018). The left and right medial orbito-frontal cortices were found to have smaller gray matter CV (Reinders et al., 2018). The dorsolateral prefrontal cortex/middle frontal cortex was found to have a smaller gray matter CV bilaterally (Reinders et al., 2019).

#### 3.2.5. Cingulate Cortices

Several structures within the Cingulate cortex were found to be smaller as documented by Reinders et al. (2018): The left and right anterior cingulate gyri were found to have smaller gray matter CV. The left cingulate gyrus was found to have smaller gray matter CV. The right caudal anterior cingulate cortex was found to have smaller gray matter CT and CV. The right isthmus of the cingulate cortex was found to have smaller gray matter CT. The right posterior cingulate cortex was found to have smaller gray matter CT and CV. The left callosomarginal sulcus/cingulate sulcus was found to have smaller gray matter SA and CV. The left and right rostral anterior cingulate cortices were found to have smaller gray matter CV.

#### 3.2.6. Frontal white matter

Smaller white matter tracts in DID patients were also reported by Reinders et al. (2019) in several areas of the right inferior frontal gyrus, left middle frontal gyrus, right middle superior frontal lobe, left premotor cortex, left precentral cortex, and left cingulate cortex. Increases in DID patient white matter were reported by Reinders et al. (2019) in the left inferior frontal gyrus, precentral/premotor region, pars triangularis, and cingulate/forceps minor.

### 3.3. Parietal lobe

#### 3.3.1. Global parietal lobe

The general volume of the entire left (LE) parietal lobe was found to be smaller in DID patients (Chalavi et al., 2015b). The gray matter SA and CT of the total, left, and right parietal cortices were also observed to be smaller in DID patients; however, only the smaller volume in left parietal cortex gray matter CT was statistically significant (Chalavi et al., 2015b).

#### 3.3.2. Surface parietal regions

The left angular gyrus was found to have smaller in gray matter CT (Reinders et al., 2018). The precuneus was found to have no difference in size between BPD w/DID and HC (Irlie et al., 2007). The left precuneus gray matter CV in DID was observed to be larger and the right precuneus gray matter CT in DID was observed to be smaller (Reinders et al., 2018). The total and left postcentral gyrus was observed to be larger (Irlie et al., 2007). Contrarily, Reinders et al. (2018) observed the right and left postcentral gyrus gray matter CV and left postcentral gyrus gray matter CV were smaller in DID patients. Reinders et al. (2018, 2019) also observed a smaller

**Table 2**

The determined strength of each included article as determined by criteria outlined in Table 1. A Strength of 4 was the cut off for inclusion.

Authors	Study design	Participation description	n-size	Intervention categories	Dependent variables	DV type	DV by category	Study quality score	Study conclusion
Chalavi et al., 2015b	Matched cross sectional	Voluntary and consent obtained. 17 with DID (all with PTSD in remission), 16 with PTSD, 32 matched healthy control. 4 Scans from healthy controls were excluded due to technical difficulties	65	3T MRI, MPRAGE – sed, T1 weighted, TR=9.95 ms, TE=5.6 ms,- flip angle=8 degrees, slice thickness=1 mm, isotropic voxel, 160 slices, total time 10 min and 14 s Analyzed with FREE SURFER	CT and CV	Voxel	MRI voxel	7	Larger putamen and pallidum volumes; found to be associated with more severe dissociative symptoms
Chalavi et al., 2015a	Matched cross-sectional	17 DID (all had also PTSD), 16 PTSD, 32 HC Matched: age, sex, edu, (Western European) origin Diagnosis: 1 of 2 experts, DSM-iv (SCID-D), SDQ-5, TEC, CTQ	65 F	3T Philips MRI: MPRAGE, Two 3T MR Scanners, UMCG and AMC Phillips BEST ML, TE=5.6 ms, TR=9.95 ms, flip ang=8 deg, slices=160, 1 × 1 × 1 voxels, tot time=10 min14 s Measurements: MultiTracer (manually), FreeSurfer v5.1 Stats: ANCOVA	CT and CV	Voxel	MRI voxel	7	Smaller Hippocampal volume Deformed shape negative correlation with symptom severity
Ehling et al., 2007	Matched cross-sectional	10 DID, 13 DDNOS, 10 recovered DID (phase-oriented psychotherapy), 20 HC Matched: age, sex, edu Diagnosis: DSM-iv (SCID-D), SDQ-20, TEC, PTSD-sr, HSCL-90	53 F	1 T Philips MRI: TE=4.7 ms, TR=30 ms, 1.5 gapless slices, flip ang=30 deg, slices=100–112, FOV 100%, 256 × 192 nm Matrix, tot time=10 min14 s Dissociation questionnaire, Somatoform dissociation Questionnaire, traumatic experience checklist, PTSD self-report checklist, Hopkins symptom checklist Measurements: manually Stats: ANOVA (SPSS 11.0)	CT and CV	Voxel	MRI voxel	7	Large decrease in hippocampal volume in DID, less hippocampal volume in recovered DID, decrease in Amygdala and Parahippocampal gyrus
Irlle et al., 2007	Matched cross sectional	30 BPD (7 with DA, 4 with DID, 11 with PTSD), 25 healthy matched controls	55	Philips gyrosan, 1.5T MRI, T1 weighted 3-D, TE=6 ms, TR=24ms, flip angle=30 degrees, field of view is 256, sagittal slices, matrix 256 × 256, slice thickness 1.3 mm, number of slices 130, processed with CURRY and reformatted to continuous 1 mm thick slices	CT and CV	Voxel	MRI voxel	7	Larger left vs right postcentral gyrus volumes of BPD subjects with DID or DA as opposed to without or to the controls. Larger left postcentral might relate to more severe dissociative state or to developing DA or DID
Reinders et al., 2019	Matched cross-sectional	32 DID, 43 HC Matched: age, sex, edu, (Western European) origin Diagnosis: DSM-iv (SCID-D), DES, SDQ, CDS, TEC	75 F	3T Philips MRI (across three centers): MPRAGE, T1 weighted MR, TE=5.6 ms, TR=9.95 ms, flip ang=8 deg, slices=160, 1 × 1 × 1 mm cubed Voxels, tot time=10 min14 s Measurements: SPM8, GPCs	CT and CV	voxel	MRI voxel	7	Wide abnormal patterns in white and gray matter

Table 2 (Continued)

Authors	Study design	Participation description	n-size	Intervention categories	Dependent variables	DV type	DV by category	Study quality score	Study conclusion
Reinders et al., 2018	Matched cross sectional	32 females with DID (29 with PTSD, 3 had PTSD in remission), 43 matched healthy controls	75	3T Philips MRI, MPRAGE - sed, T1 weighted, TR=9.95ms, TE = 5.6ms, flip angle = 8 degrees, slice thickness = 1 mm, isotropic voxel, 160 slices, total time 10 min and 14 s Analyzed with FREE SURFER	CT and CV	Voxel	MRI voxel	7	DID had significantly smaller total gray matter volume compared to healthy controls. Smaller cortical thickness in left insular cortex to dorsolateral orbitofrontal cortex (BA 44/45/47), cingulate cortex, left temporoparietal junction (BA 19/39), the left pre-central and postcentral gyrus, and right temporal lobe
Stein et al., 1997	Matched cross sectional	21 trauma survivors (5 with DID), 21 matched healthy controls	42	Siemens Magnetom SP63 helicon SE2 1.5 T MRI, > T1: TR=550 ms, TE = 14 ms, flip angle=65 degrees, slice thickness = 5 mm, field of view = 230 mm, matrix = 256 × 256, > T2: TR=4000 ms, TE=90 ms, slice thickness = 4 mm, interslice gap = 0.4 mm, matrix 335 × 512, field of view = 260 mm	CT and CV	Voxel	MRI voxel	7	No right sided difference
Tsai et al., 1999	Case study	1 patient with DID	1	1.5 T MRI, TE=70 ms, TR=2 ms, flip angle=90 degrees, matrix is 64 × 128	CT and CV	Voxel	MRI voxel	4	Criticism -> patient-controlled switch
Vermetten et al., 2006	Matched cross sectional	15 females with DID (all with PTSD), 23 matched healthy controls	38	SIGNA MRI, 1.5 T MRI, sagittal cuts, T1 weighted 3-D, TR = 24 ms, TE = 5 ms, flip angle = 45 degrees, matrix 256 × 196, field of view = 30 cm, slice thickness = 1.2 mm, coronal 1 mm thickness cuts reconstructed and uploaded to SunSparc and analyzed with ANALYZE	CT and CV	Voxel	MRI voxel	7	Smaller hippocampus and amygdala seen in DID patients
Weniger et al., 2008	Matched cross sectional	23 female trauma survivors (10 with PTSD, 13 with DA/DID), 25 matched healthy controls	48	Phillips gyroskan 1.5T MRI, T1 weighted 3-D, TE=6 ms, TR=24 ms, flip angle=30 degrees, field of view = 256, sagittal slices, matrix is 256 × 256, slice thickness = 1.3 mm, 130 slices Uploaded CURRY for manual analysis	Cortical thickness and volume	Voxel	MRI voxel	7	Little difference between DA and DID so they were combined

Chalavi et al., 2015a: Chalavi, S., Vissia, E. M., Giesen, M. E., Nijenhuis, E. R. S., Draijer, N., Cole, J. H., ... Reinders, A. A. T. S. (2015). Abnormal hippocampal morphology in dissociative identity disorder and post-traumatic stress disorder correlates with childhood trauma and dissociative symptoms. *Human Brain Mapping*, 36(5), 1692–1704. <https://doi.org/10.1002/hbm.22730>; Chalavi et al., 2015b: Chalavi, S., Vissia, E. M., Giesen, M. E., Nijenhuis, E. R. S., Draijer, N., Barker, G. J., ... Reinders, A. A. T. S. (2015). Similar cortical but not subcortical gray matter abnormalities in women with posttraumatic stress disorder with versus without dissociative identity disorder. *Psychiatry Research - Neuroimaging*, 231(3), 308–319. <https://doi.org/10.1016/j.pscychresns.2015.01.014>.

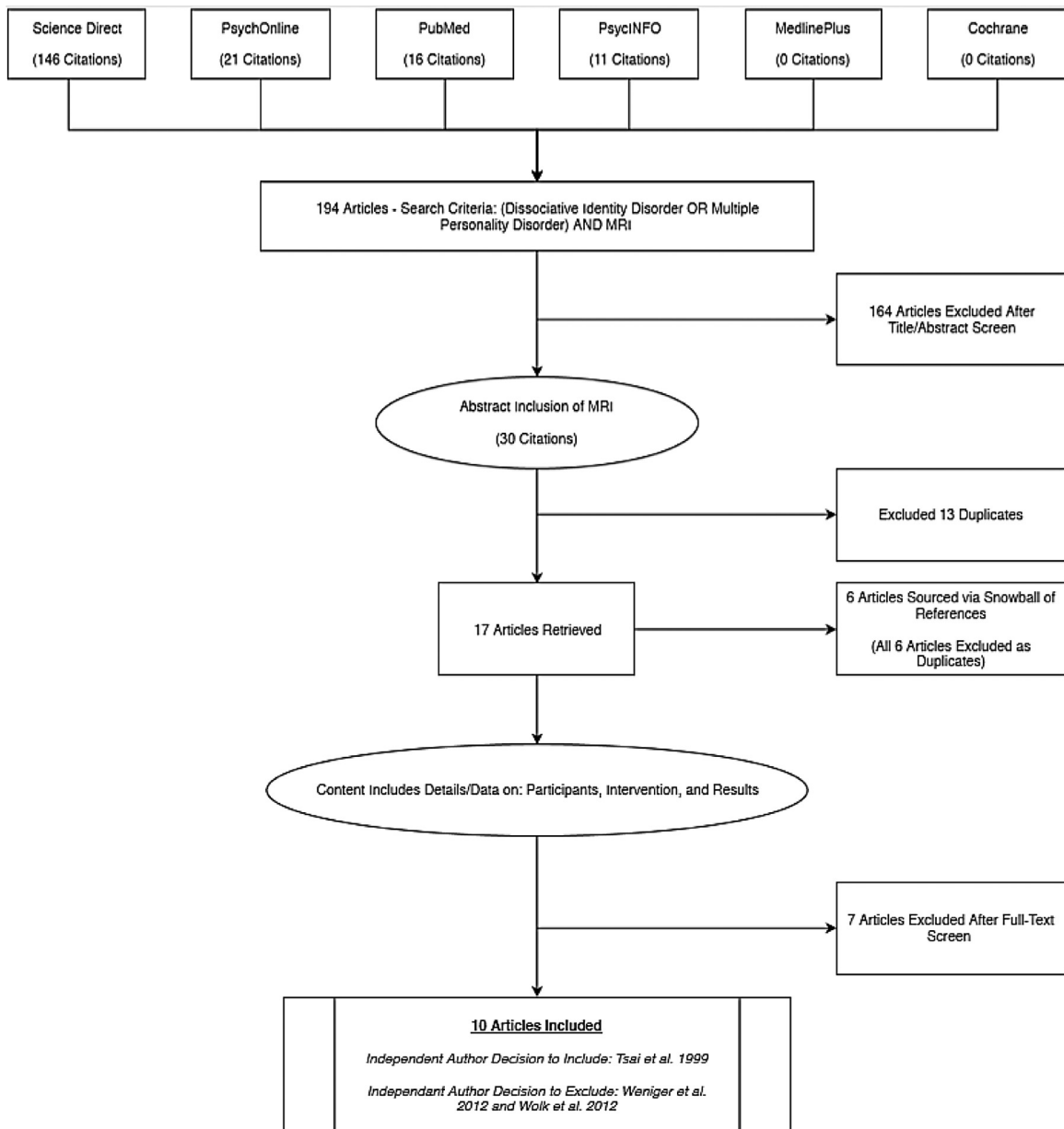


Fig. 1. PRISMA flowchart outlining how articles were included and excluded.

left superior parietal cortex gray matter CV and CT, smaller left inferior parietal lobe gray matter CV and SA and CT, larger left medial posterior parietal cortex gray matter CV, larger left medial posterior parietal/precuneus gray matter CV, and a smaller left supramarginal gyrus gray matter CV.

### 3.3.3. Parietal white matter

Reinders et al. (2019) observed the following changes in parietal white matter in DID patients: smaller left inferior parietal lobule CV, larger left superior parietal lobule CV, larger left supramarginal posterior division CV, and larger left precuneus CV.

## 3.4. Temporal lobe

### 3.4.1. Global temporal lobe

Temporal structures have been found to be altered in patients with DID, most significantly the cortical volume. There was significantly smaller cortical volume found for total and bilateral temporal lobe (Chalavi et al., 2015b).

### 3.4.2. Surface temporal regions

Reinders et al. (2018) observed a variety of changes in the temporal lobes of DID patients: smaller right and bilateral inferior temporal gyrus gray matter CV, smaller right inferior temporal gyrus/fusiform gyrus gray matter CV, smaller right middle temporal gyrus gray matter CV and CT, smaller left middle temporal gyrus gray matter CV and SA, smaller bilateral middle superior temporal gyrus gray matter CV, smaller left and right fusiform gyrus gray matter CV, smaller left superior temporal gyrus gray matter CT and CV and SA, smaller right superior temporal gyrus gray matter CV and CT, smaller left superior temporal sulcus gray matter CV and SA, smaller left temporal pole gray matter CT and CV, left transverse temporal cortex gray matter CT and CV.

### 3.4.3. Temporal White Matter

Reinders et al. (2019) found that found that, in DID patients, white matter CV was smaller in the right inferior temporal gyrus (anterior division) and the right temporal pole region but larger in the right middle temporal gyrus and left fusiform gyrus.

### 3.5. Limbic System

#### 3.5.1. Hippocampus

Bilateral hippocampal volumes in DID participants compared to HC were observed to be significantly smaller (Vermetten et al., 2006). Chalavi et al. (2015b) found a significantly smaller size of the hippocampus bilaterally in DID-PTSD patients compared to those of PTSD-only patients. A pattern was noted for PTSD-only patients of a smaller right sided hippocampus compared to left, though this does not seem to be mirrored in DID-PTSD patients (Chalavi et al., 2015a). More specifically, patients with DID-PTSD were reported to have significantly smaller volumes of the CA1, CA2-3, and CA4-DG (Chalavi et al., 2015a). Significantly smaller sizes of the subiculum and left presubiculum were also noted compared to control (Chalavi et al., 2015a). When compared to the PTSD-only group, the CA4-DG and subiculum of the DID patients were observed to be significantly smaller (Chalavi et al., 2015a). A significant correlation was noted between severity of trauma and the sizes of the CA1, CA2-3, CA4-DG, subiculum, and presubiculum (Chalavi et al., 2015b). Stein et al. (1997) observed a smaller in hippocampal volume in DID-PTSD participants compared to controls. Ehling et al. (2007) observed that participants with DID had a significantly smaller hippocampal volume as compared to controls.

It was also found that participants who recovered from DID had larger hippocampi than those who were not recovered or had completed therapy (Vermetten et al., 2006). Ehling et al. (2007) also found a negative correlation between the size of the hippocampus and performance on the DIS-Q, SDQ-20, PTSD-er, and HSCL-90. Between DID-PTSD participants, PTSD-only, and healthy controls, Weniger et al. (2008) observed that the hippocampus in patients with PTSD-only showed the most reduction in size, whereas the DID-PTSD and the controls did not significantly differ. On fMRI analysis, Tsai et al. (1999) observed bilateral inhibition of the hippocampus in DID-PTSD patients as compared to normal limits.

#### 3.5.2. Parahippocampal Gyri

Ehling et al. (2007) documented a smaller volume of the parahippocampal gyri in DID participants as compared to HC. There was no significant difference seen in the parahippocampal size between participants who recovered from DID and those who did not recover (Ehling et al., 2007). In an fMRI study of a DID patient, Tsai et al. (1999) observed inhibition of the right parahippocampal gyrus during personality switching compared to standard normal individuals. When comparing different personalities in DID patients, Schlumpf et al. (2013) observed an increase in the activation of the parahippocampal gyrus when DID participants were in the dissociated state compared to their basal state.

#### 3.5.3. Amygdala

Bilateral amygdala volumes in DID participants compared to controls were found to be significantly smaller (Vermetten et al., 2006). Ehling et al. (2007) also noted a significantly smaller amygdalar volume in DID participants compared to controls. There was no association found between degree of trauma and the resultant size of the amygdala (Ehling et al., 2007).

Chalavi et al. (2015a) found a preservation in amygdalar volume in DID patients compared to controls. When comparing DID-PTSD participants against PTSD-only and healthy controls, Weniger et al. (2008) demonstrated that the amygdala was smaller in PTSD-only group when compared to controls. On the contrary, the DID-PTSD group did not have a significant difference compared to controls (Weniger et al., 2008).

### 3.6. Occipital lobe

#### 3.6.1. Global occipital lobe

No changes in global occipital lobe structures were observed, see Supplemental Table 1.

#### 3.6.2. Occipital Gyri

Reinders et al. (2018, 2019) reported smaller gray matter CV of the right superior occipital gyrus, left superior occipital sulcus, left lateral occipital cortex, left middle occipital gyrus, and left inferior occipital gyrus. Smaller gray matter CT of the left lateral occipital cortex was also observed (Reinders et al., 2018).

#### 3.6.3. Occipital white matter

Reinders et al. (2018) found that DID patients had smaller white matter CV in the bilateral lateral occipital regions, left lateral inferior occipital region, and bilateral lateral superior occipital regions with larger white matter CV in the right middle occipital region.

### 3.7. Insular cortex

Chalavi (2015a) found a significantly smaller volume of the TE insula ( $p < 0.001$ ) and left insula ( $p < 0.001$ ). The left insular SA showed to be statistically significantly smaller ( $p = 0.005$ ) (Chalavi et al., 2015b). Reinders et al. (2019) found a smaller left insular white matter CV.

### 3.8. Other

#### 3.8.1. Basal Ganglia

**3.8.1.1. Putamen and Pallidum.** Chalavi (2015a) found a significantly larger volume of the right pallidum in DID-PTSD patients, however, DID-PTSD patients demonstrated larger bilateral putamen and right pallidum compared to PTSD-only patients. ( $p \leq 0.05$ ). When DID-PTSD was compared with PTSD-only patients, there was a significant correlation between dissociative symptoms and putamen and pallidum size ( $p \leq 0.01$ ) (Chalavi et al., 2015b). A larger volume of the left putamen white matter was also seen in Reinders et al. (2019).

**3.8.1.2. Caudate.** Within the caudate, Chalavi et al. (2015a) documented a statistically significantly larger CV of the total caudate gray matter and left caudate gray matter.

**3.8.1.3. Nucleus Accumbens.** No significant differences in the nucleus accumbens were observed, see Supplemental Table 1.

#### 3.8.2. Periaqueductal grey matter

A significantly smaller left periaqueductal gray matter was noted by Reinders et al. between DID participants and HC ( $p < 0.01$ ) (Reinders et al., 2019).

#### 3.8.3. Corticospinal tract

In DID patients, left corticospinal tract white matter CV was found to be smaller and the right corticospinal tract white matter CV was found to be larger (Reinders et al., 2019).

#### 3.8.4. Brainstem (midbrain)

Reinders et al. (2019) found that DID patients have a larger white matter CV of the left midbrain.

### 3.9. Variable results

Reinders et al. (2019) found voxel patterns that contributed to positive and negative structural patterns in the white matter



regions of DID patient brains: the right middle frontal region, the bilateral superior frontal region, the right premotor cortex, the left anterior cingulate cortex, the left cingulate, the right insula, the left temporal pole, the right inferior temporal region (anterior division), and the bilateral crus I of the cerebellum. These results suggest a high degree of variability in these tracks.

#### 4. Discussion

The purpose of this systematic review was to compile and examine the existing literature on the neuroanatomy associated with DID diagnosis measured using magnetic resonance imaging (MRI). The rationale for compiling the data was to examine the evidence (i.e., validity) for a distinct disorder, provide a foundation for more reliable diagnostic criteria, and reveal any potential research gaps. The similarities between the clinical presentation of PTSD and DID require a reliable way to differentiate PTSD with DID and without DID. Dissociate symptom subtypes as well as DID have also been co-diagnosed in BPD patients (Irle et al., 2007). Further, it has been debated whether DID can exist without PTSD considering that trauma precedes virtually all DID cases (Vermetten et al., 2006; Weniger et al., 2008). The imaging studies reviewed here offer insight into how DID can be reliably distinguished from other similarly presenting disorders. The evidence for a distinct DID is building.

##### 4.1. Whole brain

Given the previously documented studies examining global changes in PTSD patients (Vermetten et al., 2006; Weniger et al., 2008), it is expected that DID patients will demonstrate differences in their brains as well. The smaller global brain volume, thickness, surface area, and subcortical area could be due to the brain responding to excess glucocorticoids associated with trauma (Chalavi et al., 2015b; Vermetten et al., 2006). However, the smaller size is seen in other psychological disorders like PTSD, BPD, and DA (Weniger et al., 2008); though BPD patients were observed to have smaller brains than the DID patients (Irle et al., 2007). This could be due to other biochemical mechanisms that differ between the development of BPD and DID. Therefore, although the smaller global size is an important finding in DID patients, it is unlikely to be a reliable distinguishing neuroanatomical biomarker at this time.

##### 4.2. Frontal cortex

###### 4.2.1. Global frontal cortex

The frontal lobes underly executive functions (inhibition, decision making, emotional regulation, abstract and rational problem solving, etc.) and drive motor control (desire to move, execute movement programming, coordination of fine and gross movement, etc.). Thus, DID patients are expected to have modifications in this region. Executive functions are distributed diffusely. This could translate into a smaller cortical thickness of the frontal lobes in DID patients given the common symptoms of dissociation, multiple personalities, and cognitive dissonance (Siegel & Sapru, 2015). The smaller CT of the left frontal cortex with preserved total CV and SA and larger right SA suggests that, despite an overall reduction of the left frontal lobe, new connections may have formed (see Supplemental Table 1). As the frontal lobe still undergoes neurological development and differentiation in young adults, it is highly impacted by stress and trauma (Chalavi, 2013). The smaller sizes of various frontal regions in DID patients, including Broca's area, anterior cingulate cortex, and deep cingulate regions, support the idea that trauma negatively influences the frontal cortices.

###### 4.2.2. Motor Regions

The primary motor cortex in the precentral gyrus is the output center of the somatic motor fibers and communicates with the premotor cortex and other association areas. Alters and hosts have different mannerisms, handedness, and physical skill levels (Chase & Phillips, 1987; Schreiber, 1973; West, 1999). It might be expected that larger motor regions are associated with carrying out different functions; however, this was not observed in the DID patients included in our review. However, a greater amount of white matter in the motor regions in the brainstem and right hemisphere was observed (see Supplemental Table 1). It is theorized that victims with DID have suffered a fracture to the core personality (Hawksworth & Schwartz, 1977). The different mannerisms, handedness, and physical skill levels seen between alters and the host may be explained by disparate interconnections between the primary motor cortex and other key activation centers rather than increased gray matter in the primary motor cortex per se. Alters then could manifest through different circuits between cortical regions for movement, which may explain the increased white matter in the right hemisphere.

###### 4.2.3. Pars Regions

Gray matter in DID patients was shown to be reduced in volume in the Broca's area, specifically the pars Opercularis in the left and right hemispheres. Broca's area, near the pars opercularis and pars triangularis, is responsible for speech fluency. Damage here can lead to mutism (Haines, 2015). Reduced gray matter in these regions could be associated with flat affect, disengagement, and reduced emotional expression (Fahim et al., 2005; Fanti, Panayiotou, Lombardo, & Kyranides, 2016), symptoms that may be seen in patients with DID.

###### 4.2.4. Orbito-Frontal Cortex

The orbito-frontal cortex plays a part in the fear network and linking perception to emotion (Siegel & Sapru, 2015). Yakovlev was the first to include the orbito-frontal cortex (OFC) as part of the fear circuit, originally described by MacLean (Catani, Dell'Acqua, & Thiebaut de Schotten, 2013; Siegel & Sapru, 2015). In Catani's diagram of the circuit, the OFC connects to both the thalamus and the amygdala (Catani et al., 2013). A smaller OFC, as seen in DID (Reinders et al., 2019), could be associated with an abnormal or prolonged fear response without extinction (Milad & Rauch, 2007) or it could be a predetermining factor in the pathology of DID. DID patients utilize neurotic defense mechanisms, dissociation and derealization, to process trauma and fear toward assailants and situations that remind them of the traumatic event (APA, 2013). This type of brain region reduction has previously been shown in PTSD (Chalavi et al., 2015a; Irle et al., 2007; Weniger et al., 2008), and DID is often considered the most severe manifestation of childhood trauma, as described above.

###### 4.2.5. Anterior Cingulate Cortex

The anterior cingulate cortex (ACC) has autonomic, emotive, and rational functions involved in problem-solving during the early stages of learning (Bush, Luu, & Posner, 2000; Lockwood & Wittmann, 2018). The ventral aspect of the ACC is connected to the amygdala and anterior insula, and the ventral aspect of the ACC assesses motivations and emotions of self (Bush et al., 2000). Lesions in the ACC can lead to akinetic mutism, inattention, and profound apathy (Lockwood & Wittmann, 2018; Siegel & Sapru, 2015). It has also been suggested that the ACC has a role in the action-outcome association needed for motivation (Kurniawan, Guitart-Masip, & Dolan, 2011; Lockwood & Wittmann, 2018). This reward learning can be achieved through error monitoring and analyzing emotional cues that occur in the ACC (Bush et al., 2000; Kurniawan et al., 2011; Lockwood & Wittmann, 2018). Another

interesting function of the ACC is its relationship to fear memory modification (Lawless, 2017). DID patients often have issues with emotional regulation (Reinders et al., 2012), fear processing and learning (Vermetten et al., 2006), interpreting emotion (Schlumpf et al., 2013), and even motivational issues similar to that seen in depressed patients (APA, 2013). Given that many structures within the cingulate cortex and ACC are involved in these processes, and these structures are significantly smaller in DID patients (see Supplemental Table 1), it can be expected that DID patients would show deficits in emotional regulation, fear processing and learning, and interpreting emotion.

#### 4.3. Parietal Cortex

##### 4.3.1. Global Parietal Cortex

The parietal lobe supports the perception and processing of somatosensory events with the postcentral gyrus serving as the primary receiving area for somesthetic information from the body. The volume of the parietal cortex has been shown to have a negative correlation with the severity of dissociative symptoms (Chalavi et al., 2015b). Other studies have demonstrated the ability to induce out of body events via electrical stimulation of the parietal lobe (Siegel & Sapru, 2015). This suggests that the parietal cortex may have a role in depersonalization and dissociative symptoms. Paradoxically, this may indicate that the smaller size and overstimulation of the parietal lobe both can lead to dissociation and depersonalization. Lesions within the parietal cortex have also been observed to cause agnosia and loss of somatosensation, supporting the potential role of smaller parietal size with dissociation (Haines, 2015; Siegel & Sapru, 2015). This is consistent with reduced parietal cortex gray matter seen among DID patients in our review (see Supplemental Table 1).

##### 4.3.2. Surface Parietal Regions

The inferior parietal and supramarginal gyrus receive input from auditory and visual cortices to perform complex perceptual discrimination, acting as the secondary somatosensory cortex (S2) (Siegel & Sapru, 2015). The lateral portion of parietal lobe includes the inferior parietal lobe. This is subdivided into the supramarginal and angular gyri, which are responsible for bilateral phonological and semantic processing of words, respectively (Siegel & Sapru, 2015). The inferior parietal lobe is largely connected to Wernicke's language area in the left hemisphere and acts as another association area for somatosensation (Haines, 2015). The left angular gyrus also deals with verbal arithmetic and fact retrieval, whereas the right angular gyrus integrates knowledge and location (Siegel & Sapru, 2015). While the angular gyrus is often cited as functioning in language, additional functions include control of attention shifts, awareness of intended and consequential movements, interpretation of a person's intentions, and experience of out-of-body phenomena (Arzy, Seeck, Ortigue, Spinelli, & Blanke, 2006). The postcentral gyrus, primary somatosensory cortex (S1), has been shown to be recruited in tasks that require taking a first-person perspective and a larger postcentral gyrus may be associated with increased dissociative states (Irle et al., 2007). The parietal cortex may be critically associated with DID symptomatology. Smaller inferior parietal cortex could underly issues of expression, interpretation, and derealization seen in the different manifesting alters of DID patients. The smaller angular gyrus and supramarginal gyrus size could explain why DID patients sometimes have difficulty with expression and self-awareness.

##### 4.3.3. Precuneus

The precuneus is a highly developed association cortex of the medial parietal cortex that controls voluntary attention shifts in spatially guided behavior and episodic-related retrieval tasks

(personal experience) (Irle et al., 2007). The precuneus also acts as a link between personal identity and past experiences (Catani et al., 2013; Siegel & Sapru, 2015). The Precuneus is associated with the highest resting perfusion rate in the cerebral cortex (Irle et al., 2007). One implication of these characteristics could be that the precuneus would be tonically active in order to gather information to create a perspective of the subject relative to their environment. The precuneus has also been shown to be active while imagining one's own actions (Irle et al., 2007). Further, Irle et al. (2007) observed that a larger right precuneus in BPD was associated with more depersonalization. Contrary to this finding, Reinders et al. observed that the left precuneus was the larger region in DID patients (Reinders et al., 2019). Despite this disagreement, the precuneus most likely plays a role in DID, particularly in relation to DID symptoms such as dissociative amnesia, depersonalization, derealization, identity confusion, and identity alteration.

#### 4.4. Temporal Cortex

The middle temporal gyrus functions in the perception of moving objects in the visual field while the superior temporal gyrus functions in auditory perception (Siegel & Sapru, 2015). The inferior temporal gyrus functions in the general recognition and the fusiform gyrus is involved in facial recognition (Schlumpf et al., 2013; Siegel & Sapru, 2015). Neurophysiologically, the temporal neurons have a low threshold for seizure discharges (Schmidek & Sweet, 2012; Siegel & Sapru, 2015). During seizures, the subject experiences auditory, olfactory, vertiginous, and/or gustatory hallucinations. The temporal lobe also contains the Meyer's loops, which is responsible for upper quadrant vision (Haines, 2015). Electrical stimulation of the temporal cortices, like stimulation of the parietal cortices, has been associated with dissociative states (Irle et al., 2007). Like the parietal lobe, several structural volumes in the temporal cortex have been observed to be smaller in DID patients, potentially explaining the derealization of the host when an alter takes control.

#### 4.5. Limbic system

The limbic system is a set of structures that lie deep within the cortex, and is primarily involved in processing memories and emotion, though it also plays a role in behavioral, endocrine, and autonomic functioning. Changes in this lobe associated with DID have been well established in the literature, however, the exact differences in these structures that can be seen between DID and PTSD have not been fully uncovered due to the degree of overlap (Vermetten et al., 2006; Weniger et al., 2008). The volume and shape of the hippocampus, parahippocampal gyrus, and amygdala, however, have repeatedly been shown to be smaller, or functionally altered, in DID patients in comparison to matched controls (Chalavi et al., 2015b; Ehling et al., 2007).

##### 4.5.1. Hippocampus

Vermetten et al. (2006) have shown smaller hippocampal and amygdalar volumes in DID patients; a result that has been corroborated by subsequent researchers (Chalavi et al., 2015b; Weniger et al., 2008). There appears to be a negative correlation between the degree of traumatization and the size of the hippocampus in patients with DID (Chalavi et al., 2015b; Chalavi et al., 2015a; Reinders et al., 2019). Therefore, we speculate that a DID patient who experiences a more prolonged or more intense traumatic event can be expected to have a smaller observed hippocampal volume on MRI as compared to a DID patient who experiences a less traumatic event. One possible explanation for this is that, when exposed to an extreme and prolonged stressor, glucocorticoids saturate the hippocampus (Chalavi et al., 2015b).

This continuous assault on the hippocampus over time can lead to gray matter reduction (Vermetten et al., 2006). More specifically, the hippocampal substructures CA2-CA3, CA4-DG, and the subiculum have been observed to have the greatest changes in morphology following extended exposure to increased amounts of glucocorticoids (Chalavi et al., 2015a). With this established, the impact of therapy and treatment of DID in hippocampal structure preservation may be substantial. Ehling et al. (2007) demonstrated that DID patients who recovered following therapy had larger observed hippocampal volumes than those who were not recovered. Ehling et al. (2007) also observed that abused non-DID participants had larger amygdalar and hippocampal volumes than non-abused non-DID, further suggesting a protective function of volume. This finding, however, was not mirrored in the parahippocampal gyrus or the amygdala of DID patients (Ehling et al., 2007). Further longitudinal research in this area could reveal novel implications of therapy on the morphological changes in DID patients with further discussion as to the causality and direction of hippocampal changes.

#### 4.5.2. Parahippocampal Gyrus

The parahippocampal/fusiform gyrus is often impacted in DID patients (see Supplemental Table 1). These areas have been associated with intrusions and recall symptoms that are classically seen in PTSD patients (Weniger et al., 2008). An fMRI of DID participants demonstrated similar activation patterns to those with PTSD when in an emotionally dissociated state (Schlumpf et al., 2013). Differences between DID and control patients also seem to be far more pronounced when in this emotionally dissociated state. That is, the parahippocampal gyri in DID patients show an aspect of over-activation when in the dissociated state as compared to under-activation seen in the neutral, or control, state (Schlumpf et al., 2013). These state-dependent activation changes on fMRI are also seen in some hippocampal case studies (Tsai et al., 1999). Given these findings, it can be inferred that the parahippocampal gyrus plays a role in the pathology of DID.

#### 4.5.3. Amygdala

Like the hippocampus, the amygdala was smaller size and shape in DID patients compared to healthy controls (Vermetten et al., 2006). However, this result has seemed inconsistent when compared to the hippocampus, with some studies showing a smaller size and others showing no change (Chalavi et al., 2015b). For example, Weniger et al. (2008) reported a conservation of amygdalar and hippocampal size in DID patients compared to control and PTSD patients. However, Weniger used a small sample to attempt to disentangle PTSD from DID morphology and was unable to separate his DID and DA patients (see Table 2). Therefore, the accuracy and application of his conclusions may be limited.

Furthermore, the apparent size of the amygdala is not a definitive measure of its functioning. Chalavi et al. discussed some inconsistencies in amygdalar volume findings in the field (Chalavi et al., 2015b). Even though variations exist in the literature, the majority of current research favors a loss of amygdalar volume and function in DID compared to controls. Specifically, depersonalization has been associated with changes in left amygdala and the left amygdala-hippocampal junction (Irle et al., 2007; Reinders et al., 2019). Unlike the hippocampus, this smaller volume cannot be explained by a similar glucocorticoid hypothesis as discussed above (Vermetten et al., 2006). We speculate that a decrease in amygdalar function and size could play a critical role in manifestation of DID. The defense mechanisms used by DID patients, specifically, the creation of new personalities during trauma, involve a break down in proper fear handling (Şar et al., 2017). A patient with a smaller or less functional amygdala could be more likely to utilize defense mechanisms like dissociation. Further

investigation is warranted to elucidate the specific reasons for the amygdalar changes.

#### 4.6. Occipital cortex

The occipital cortex and its substructures all play vital roles in vision, object localization, and complex perception analysis. The current research shows that the majority of patients with DID have smaller occipital regions, both gray and white matter (see Supplemental Table 1). Though research has not been conducted into visual deficits of DID patients, we speculate that this finding could be expected because of DID patients show decreased accuracy in identifying emotive facial expressions and sensory derealization during and after trauma (Schlumpf et al., 2013). Additional research is needed to better identify a more reliable way of establishing and implementing occipital cortex changes in DID patients.

#### 4.7. Insula

The insula is a subcortical structure that has higher functions like the integration and analysis of gustatory, auditory, and olfactory signals as well as processing memories and emotions (Siegel & Sapru, 2015). Though there are few studies investigating the insula, the results all support a smaller insular volume in DID patients (see Supplemental Table 1). We speculate that a small insular cortex in DID patients could increase the likelihood of hallucinations and episodes of derealization such as the separation of self DID patients suffer during trauma. Additional research needs to be done in order to examine this possible relationship.

#### 4.8. Other Brain Structures

##### 4.8.1. Basal Ganglia

The basal ganglia are located deep within the cerebral hemispheres. It is a group of structures that are highly interconnected within themselves and other structures. The basal ganglia have a role in many functions including motivation, movements, decision making, and memory. The putamen and pallidum have demonstrated significantly larger volume in DID patients (Reinders et al., 2019). An interesting difference was also noted by Chalavi et al. (2015a) who observed a larger putamen and pallidum size in DID-PTSD patients compared to PTSD only patients. The larger size of these structures is also positively correlated with the degree of depersonalization and dissociative symptoms seen in DID-PTSD patients (Reinders et al., 2019). These findings are also supported by increased activity in the putamen observed in fMRI studies of DID patients observing facial expression in a dissociated state (Schlumpf et al., 2013). These volume findings may be associated with unique movement patterns and habits seen across different personalities in patients with DID. The deep brain regions could be more likely utilized by every personality because of the intrinsic relationship between deep structures and movement regulation. Future research would need to utilize fMRI and other tissue activation imaging measures to investigate this. Other structures within the basal ganglia, such as the caudate and the thalamus, have been discussed and imaged, though no significant changes have been documented (Chalavi et al., 2015b; Reinders et al., 2019).

#### 4.9. Variable Results

The structural changes outlined in section 3.9 were found to have increased and decreased voxel patterns. However, the patterns found to contribute to increased structural findings had different voxel coordinates than the patterns found to contribute to

decreased structural findings. Therefore, these variable or inconsistent results could be part of the DID pathology. That is, changes in brain morphology associated with DID might not coincide with accepted anatomical decisions in brain regions. As [Reinders et al. \(2019\)](#) are the only current authors to publish results investigating such details and differences, future research should continue to examine the voxel patterns of these structural regions to clarify increases and/or decreases within the same brain structure.

#### 4.10. Limitations

Though this novel systematic review provides evidence in support of DID, it has some limitations. Research into the neuroanatomical imaging of DID is still in its infancy. Therefore, the number of studies able to be included in this review is small, making it more difficult to extrapolate reliable measures. This systematic review does highlight the gap in the research and hopefully can be used as a template for further researchers to continue building upon the foundation that has been laid. Additionally, all the studies that were reviewed in the present work only included female participants. While this limitation may be attributable to the prevalence differences between males and females, it nonetheless calls into question whether there are differences in neuroanatomical biomarkers between men and women. Gender should be controlled in future works despite the lower prevalence of DID in males ([Beidel, Frueh, & Hersen, 2014](#)).

Another limitation to this study is that MRI is an indirect measure of brain structures. Therefore, results are limited by the capability of the technology. Future research could investigate doing post-mortem analyses of DID patient brains.

Another limitation of this study is that the compiled data was presented as a percent difference when the authors listed the calculated volumes of the DID patients and HC. The method of calculating the percent differences is limited by the accuracy of the original studies, the differences in MRI resolution that some of the authors used, and our presented percent differences are not primary data.

Finally, a major limitation of the study is the controversy surrounding the diagnosis of DID, as discussed earlier in this review. Though experts in dissociative disorders and the DES and MID were used to verify the subjects having DID, the measures themselves are not controlled for. By not having a completely reliable standard for diagnosing DID, the certainty of the anatomical changes associated with the disorder is necessarily limited by the certainty of the DID diagnosis. Despite this, training in diagnosing DID is available from experts in the field including training in implementing the DES, MID and the Structured Clinical Interview for DSM-IV Dissociative Disorders (SCID-D). The SCID-D is an interview method for diagnosing DID that has been extensively field tested ([Steinberg & Hall, 1997](#)). And even though a gold standard of diagnosis does not exist, if there is uncertainty in the DID diagnosis, a second opinion can always be gathered.

#### 4.11. Research gaps

Potential gaps in research are the need to control for sex and handedness in imaging studies. By controlling for sex, any potential neuroanatomical sexual dimorphism could be observed. By controlling for handedness, any potential association between homunculus dominance and brain region structure size or activation could be observed. As discussed above, these are two potentially confounding variables that could attribute to some of the differing results. Another gap is the need for higher resolution imaging in further research. Using digital tomography or a minimum of 3T MRI will provide more sensitive data. Despite the increase in noise and need to scan more objects that

accompanies a larger field strength, future studies all utilizing the same tesla strength would allow for meta-analysis of the data. Additionally, as imaging is one of the limitations of this review and the included articles, future research could attempt to collect primary brain volume data via dissection of DID patients.

#### 4.12. Implications and Further Considerations

This review is the first to compile the neuroanatomical changes associated with DID. While the field of inquiry is still in its infancy, evidence for a distinct and real disorder, as indicated by numerous differences in the brains of patients diagnosed with DID versus HC, is accumulating. Although a smaller global brain size is unlikely to be a reliable distinguishing neuroanatomical biomarker at this time, several other brain regions appear to be impacted in DID. There appears to be an increase in white matter tracts in the motor regions in the brainstem and right hemisphere. There is a reduction in the size of OFC, which could be associated with an abnormal or diminished fear response as speculated above. DID patients often have challenges with emotive processing, fear networks and learning, and interpreting emotion ([APA, 2013](#)). DID patients have even found to have motivational issues similar to that seen in depressed patients ([APA, 2013](#)). These symptoms may be associated with a smaller size of the cingulate cortex and ACC. The parietal cortex is integral to the manifestation of DID, and a smaller inferior parietal cortex could underly issues of expression, interpretation, and derealization seen in the different manifesting alters of DID patients. The smaller angular gyrus and supramarginal gyrus size could explain why DID patients sometimes have difficulty with expression and self-awareness. A larger precuneus size or activity could be explained by multiple personalities requiring more circuits than a single host because of the alters' need to maintain a perspective of the environment. The smaller size of temporal lobar structures could explain the derealization of the host during alter take over. There appears to be a negative correlation between the degree of traumatization and the resultant size of the hippocampus in patients with DID ([Chalavi et al., 2015b; Vermetten et al., 2006](#)). The parahippocampal/fusiform gyrus is often impacted in DID patients and has been associated with intrusions and recall symptoms ([Weniger et al., 2008](#)). The majority of current research favors a loss of amygdala volume and function in DID compared to controls. Specifically, depersonalization has been associated with changes in left amygdala and the left amygdala-hippocampal junction ([Irle et al., 2007; Vermetten et al., 2006](#)). The majority of current research favors a loss of amygdala volume and function in DID compared to controls. Specifically, depersonalization has been associated with changes in left amygdala and the left amygdala-hippocampal junction ([Chalavi et al., 2015b; Chalavi et al., 2015a; Irle et al., 2007](#)). The occipital cortex and insula also appear to be impacted in DID patients, though the implication of this reduction in structure size is not clear at this time. The documented neuroanatomical biomarkers can be used to offer support for a DID diagnosis, factually check malingering patients, and assessing victims of childhood trauma for potential existence and development of dissociative symptoms. Future work should include larger sample sizes and control for more variables in an effort to provide more explanations for DID etiopathogenesis. As research in the field grows, future reviews will be able to draw more complete neuroanatomical conclusions regarding the morphology and pathogenesis of DID.

#### Support and sponsor

This protocol and systematic review did not receive any funding nor any sponsorship by any external organizations.

## Contribution of authors

David Blihar: study design, protocol design, protocol preparation, article search, data extraction, manuscript preparation.

Elliott Delgado: protocol preparation, article search, data extraction, manuscript preparation.

Marina Buryak: protocol preparation, article search, data extraction, manuscript preparation.

Michael Gonzalez: protocol preparation, article search, data extraction, manuscript preparation.

Randall Waechter, PhD: study design, protocol design, protocol preparation, manuscript preparation.

## Disclosure of interest

The authors declare that they have no competing interest.

## Appendix A. Supplementary data

Supplementary data associated with this article can be found, in the online version, at <https://doi.org/10.1016/j.ejtd.2020.100148>.

## References

- APA. (2013). In: S. Schultz, E. Kuhl, (Eds.), *Diagnostic and Statistical Manual of Mental Disorders Fifth Edition*. Fifth edition. Arlington: American Psychiatric Association. Chapters: Bipolar and Related Disorders (p. 161–193), Trauma and Stressor Related Disorders (p. 302–328), Dissociative Disorders (p. 328–345).
- Arzy, S., Seeck, M., Ortigue, S., Spinelli, L., & Blanke, O. (2006). Induction of an illusory shadow person. *Nature*, *443*(7109), 287. <http://dx.doi.org/10.1038/443287a>
- Beidel, D. C., Frueh, C. B., & Hersen, M. (Eds.). (2014). *Adult Psychopathology and Diagnosis*. In: DC Beidel, CB Frueh, M Hersen, (Eds.), 7th ed. Hoboken: Wiley.
- Brand, B. L., Vissia, E. M., Chalavi, S., Nijenhuis, E. R. S., Webermann, A. R., Draijer, N., & Reinders, A. A. T. S. (2016). DID is trauma based: further evidence supporting the trauma model of DID. *Acta Psychiatrica Scandinavica*, *134*(6), 560–563. <http://dx.doi.org/10.1111/acps.12653>
- Bush, G., Luu, P., & Posner, M. I. (2000). Cognitive and emotional influences in anterior cingulate cortex. *Trends in Cognitive Sciences*, *4*(6), 61–68.
- Catani, M., Dell'Acqua, F., & Thiebaut de Schotten, M. (2013). A revised limbic system model for memory, emotion and behaviour. *Neuroscience and Biobehavioral Reviews*, *37*(8), 1724–1737. <http://dx.doi.org/10.1016/j.neubiorev.2013.07.001>
- Chalavi, S. (2013). *The Traumatized Brain*. Hemedan: University of Groningen.
- Chalavi, S., Vissia, E. M., Giesen, M. E., Nijenhuis, E. R. S., Draijer, N., Barker, G. J., & Reinders, A. A. T. S. (2015). Similar cortical but not subcortical gray matter abnormalities in women with posttraumatic stress disorder with versus without dissociative identity disorder. *Psychiatry Research - Neuroimaging*, *231*(3), 308–319. <http://dx.doi.org/10.1016/j.psychres.2015.01.014>
- Chalavi, S., Vissia, E. M., Giesen, M. E., Nijenhuis, E. R. S., Draijer, N., Cole, J. H., & Reinders, A. A. T. S. (2015). Abnormal hippocampal morphology in dissociative identity disorder and post-traumatic stress disorder correlates with childhood trauma and dissociative symptoms. *Human Brain Mapping*, *36*(5), 1692–1704. <http://dx.doi.org/10.1002/hbm.22730>
- Chang, E. F., Rowland, N. C., & Barbaro, N. M. (2012). Corpus callosotomy: Indications and techniques. In A. Quinones-Hinojosa (Ed.), Philadelphia, PA: Elsevier Saunders <http://dx.doi.org/10.1016/C2011-1-05132-9>
- Chase, T., & Phillips, R. A. (1987). *When Rabbit Howls*. New York: Dutton.
- Dalenberg, C. J., Brand, B. L., Gleaves, D. H., Dorahy, M. J., Loewenstein, R. J., Cardeña, E., & Spiegel, D. (2012). Evaluation of the evidence for the trauma and fantasy models of dissociation. *Psychological Bulletin*, *138*(3), 550–588. <http://dx.doi.org/10.1037/a0027447>
- Ehling, T., Nijenhuis, E. R. S., & Krikke, A. P. (2007). Volume of discrete brain structures in complex dissociative disorders: Preliminary findings. *Progress in Brain Research*, *167*, 307–310. [http://dx.doi.org/10.1016/S0079-6123\(07\)67029-0](http://dx.doi.org/10.1016/S0079-6123(07)67029-0)
- Elzinga, B. M., Van Dyck, R., & Spinhoven, P. (1998). Three Controversies About Dissociative Identity Disorder. *Clinical Psychology and Psychotherapy*, *5*, 13–23 (June 1997).
- Fahim, C., Stip, E., Mancini-Marie, A., Mensour, B., Boulay, L. J., Leroux, J.-M., & Beaugregard, M. (2005). Brain activity during emotionally negative pictures in schizophrenia with and without flat affect: An fMRI Study. *Psychiatry Research: Neuroimaging*, *140*(1), 1–15. <http://dx.doi.org/10.1016/j.psychres.2005.06.003>
- Fanti, K. A., Panayiotou, G., Lombardo, M. V., & Kyranides, M. N. (2016). Unemotional on all counts: Evidence of reduced affective responses in individuals with high callous-unemotional traits across emotion systems and valences. *Social Neuroscience*, *11*(1), 72–87. <http://dx.doi.org/10.1080/17470919.2015.1034378>
- Haines, D.E. (2015). *Neuroanatomy in clinical context. An atlas of structures, sections, systems, and syndromes*. C Taylor, (Ed.), 9th ed. Baltimore: Wolters Kluwer Health.
- Hawksworth, H., & Schwartz, T. (1977). *The five of me: The autobiography of a multiple personality*. Chicago: Henry Regnery Co.
- Irle, E., Lange, C., Weniger, G., & Sachsse, U. (2007). Size abnormalities of the superior parietal cortices are related to dissociation in borderline personality disorder. *Psychiatry Research - Neuroimaging*, *156*(2), 139–149. <http://dx.doi.org/10.1016/j.psychres.2007.01.007>
- Kurniawan, I. T., Guitart-Masip, M., & Dolan, R. J. (2011). Dopamine and effort-based decision making. *Frontiers in Neuroscience*, *5*, 81. <http://dx.doi.org/10.3389/fnins.2011.00081>
- Lawless, C. (2017). *The role of basal forebrain cholinergic projections to the anterior cingulate cortex in cued and contextual fear conditioned suppression paradigms*. Office of Laboratory Animal Medicine.
- Lockwood, P. L., & Wittmann, M. K. (2018). Ventral anterior cingulate cortex and social decision-making. *Neuroscience & Biobehavioral Reviews*, *92*, 187–191. <http://dx.doi.org/10.1016/j.neubiorev.2018.05.030>
- McAllister, M. (2000). Dissociative identity disorder: a literature review. *Journal of Psychiatric and Mental Health Nursing*, *7*, 25–33 (Middleton 1995).
- Merckelbach, H., Lynn, S. J., & Lilienfeld, S. O. (2016). Vissia and co-workers claim that DID is trauma-based. But how strong is their evidence? *Acta Psychiatrica Scandinavica*, *134*(6), 559–560. <http://dx.doi.org/10.1111/acps.12642>
- Milad, M. R., & Rauch, S. L. (2007). The Role of the Orbitofrontal Cortex in Anxiety Disorders. *Annals of the New York Academy of Sciences*, *1121*(1), 546–561. <http://dx.doi.org/10.1196/annals.1401.006>
- NIH. (n.d.). PROSPERO. Retrieved from: <https://www.crd.york.ac.uk/PROSPERO/>.
- North, C. (2015). The classification of hysteria and related disorders: Historical and phenomenological considerations. *Behavioral Sciences*, *5*(4), 496–517. <http://dx.doi.org/10.3390/bs5040496>
- Pham, M. T., Rajić, A., Greig, J. D., Sargeant, J. M., Papadopoulos, A., & McEwen, S. A. (2014). A scoping review of scoping reviews: Advancing the approach and enhancing the consistency. *Research Synthesis Methods*, *5*(4), 371–385. <http://dx.doi.org/10.1002/jrsm.1123>
- Reinders, A. A. T. S., Chalavi, S., Schlumpf, Y. R., Vissia, E. M., Nijenhuis, E. R. S., Jäncke, L., & Ecker, C. (2018). Neurodevelopmental origins of abnormal cortical morphology in dissociative identity disorder. *Acta Psychiatrica Scandinavica*, *137*(2), 157–170. <http://dx.doi.org/10.1111/acps.12839>
- Reinders, A. A. T. S., Marquand, A. F., Schlumpf, Y. R., Chalavi, S., Vissia, E. M., Nijenhuis, E. R. S., & Veltman, D. J. (2019). Aiding the diagnosis of dissociative identity disorder: pattern recognition study of brain biomarkers. *British Journal of Psychiatry*, *215*(3), 536–544. <http://dx.doi.org/10.1192/bjp.2018.255>
- Reinders, A. A. T. S., Willemsen, A. T. M., Vos, H. P. J., & Den Boer, J. A. (2012). Fact or factitious? A psychobiological study of authentic and simulated dissociative identity states. *Plos One*, *7*(6), e39279. <http://dx.doi.org/10.1371/journal.pone.0039279>
- Ross, C. A. (1998). *Book Review Dissociative Identity Disorder: Diagnosis, Clinical Features, and Treatment of Multiple Personality Disorder*. *Clinical Psychology and Psychotherapy*, *204*, 1998.
- Şar, V., Dorahy, M., & Krüger, C. (2017). *Revisiting the etiological aspects of dissociative identity disorder: A biopsychosocial perspective*. Dovepress.
- Schlumpf, Y. R., Nijenhuis, E. R. S., Chalavi, S., Weder, E. V., Zimmermann, E., Luechinger, R., & Jäncke, L. (2013). Dissociative part-dependent biopsychosocial reactions to backward masked angry and neutral faces: An fMRI Study of Dissociative Identity Disorder. *NeuroImage: Clinical*, *3*, 54–64. <http://dx.doi.org/10.1016/j.nicl.2013.07.002>
- Schmidek, D., & Sweet, D. (2012). *Operative Neurosurgical Techniques*. In: A Quiñones-Hinojosa, (Ed.), 6th ed. Baltimore: Elsevier.
- Schreiber, F. (1973). *Sybil*. Chicago: Regnery.
- Shamseer, L., Moher, D., Clarke, M., Ghera, D., Liberati, A., Petticrew, M., & Shekelle, P. (2015). PRISMA-P (Preferred Reporting Items for Systematic review and Meta-Analysis Protocols) 2015 checklist: recommended items to address in a systematic review protocol. *BMJ*, *349*, g7647.
- Siegel, A., & Saprú, H. N. (2015). *Essential Neuroscience* (3rd ed.). Philadelphia, PA: Lippincott Williams & Wilkins, a Wolters Kluwer business.
- Spanos, N. P. (1994). Multiple identity enactments and multiple personality disorder: A sociocognitive perspective. *Psychological Bulletin*, *116*(1), 143–165. <http://dx.doi.org/10.1037/0033-2909.116.1.143>
- Stein, M. B., Koverola, C., Hanna, C., Torchia, M. G., & McClarty, B. (1997). Hippocampal volume in women victimized by childhood sexual abuse. *Psychological Medicine*, *27*(4), 951–959. <http://dx.doi.org/10.1017/S0033291797005242>
- Steinberg, M., & Hall, P. (1997). The SCID-D diagnostic interview and treatment planning in dissociative disorders. *Bulletin of the Menninger Clinic*, *61*(1), 108–120. <http://www.ncbi.nlm.nih.gov/pubmed/9066180>
- Tsai, G. E., Condie, D., Wu, M. T., & Chang, I. W. (1999). Functional magnetic resonance imaging of personality switches in a woman with dissociative identity disorder. *Harvard Review of Psychiatry*, *7*(2), 119–122. <http://dx.doi.org/10.1093/hrp/7.2.119>
- van Ijzendoorn, M. H., & Schuengel, C. (1996). The measurement of dissociation in normal and clinical populations: Meta-analytic validation of The Dissociative Experiences Scale (DES). *Clinical Psychology Review*, *16*(5), 365–382.
- Vermetten, E., Schmahl, C., Lindner, S., Loewenstein, R., & Bremner, J. D. (2006). Hippocampal and Amygdalar Volumes in Dissociative Identity Disorder. *American Journal of Psychiatry*, *163*(4), 630–636. <http://dx.doi.org/10.1176/appi.ajp.163.4.630.Hippocampal>
- Vissia, E. M., Giesen, M. E., Chalavi, S., Nijenhuis, E. R. S., Draijer, N., Brand, B. L., & Reinders, A. A. T. S. (2016). Is it Trauma- or Fantasy-based? Comparing dissociative identity disorder, post-traumatic stress disorder, simulators, and controls. *Acta Psychiatrica Scandinavica*, *134*(2), 111–128. <http://dx.doi.org/10.1111/acps.12590>

- Watkin, J. G. (1984). The bianchi (L.A. hillside strangler) case: Sociopath or multiple personality? *International Journal of Clinical and Experimental Hypnosis*, 32(2), 67–101. <http://dx.doi.org/10.1080/00207148408416005>
- Weingarten, D. M., Asthagiri, A. R., Butman, J. A., Sato, S., Wiggs, E. A., Damaska, B., & Heiss, J. D. (2009). Cortical mapping and frameless stereotactic navigation in the high-field intraoperative magnetic resonance imaging suite. *Journal of Neurosurgery*, 111(6), 1185–1190. <http://dx.doi.org/10.3171/2009.5.JNS09164>
- Weniger, G., Lange, C., Sachsse, U., & Irle, E. (2008). Amygdala and hippocampal volumes and cognition in adult survivors of childhood abuse with dissociative disorders. *Acta Psychiatrica Scandinavica*, 118(4), 281–290. <http://dx.doi.org/10.1111/j.1600-0447.2008.01246.x>
- West, C. (1999). *First Person Plural*. New York: Hyperion.
- West, S., King, V., Carey, T., Lohr, K., McKoy, N., Sutton, S., & Lux, L. (2002). *Systems to Rate the Strength Of Scientific Evidence. Evidence Report/Technology Assessment*.